

Xenograft Tumor Volume Measurement in Nude Mice: Estimation of 3D Ultrasound Volume Measurements Based on Manual Caliper Measurements

Mustafa Mahmut Baris¹, Efe Serinan², Meryem Calisir³, Kursat Simsek¹, Safiye Aktas², Osman Yilmaz³, Sevgi Kilic Ozdemir⁴, Mustafa Secil¹

¹Dokuz Eylul University School of Medicine, Radiology, Izmir, Turkey

²Dokuz Eylul University Institute of Oncology, Basic Oncology, Izmir, Turkey

³Dokuz Eylul University, Laboratory of Animal Science, Izmir, Turkey

⁴Izmir Institute of Technology, Chemical Engineering, Izmir, Turkey

Address for Correspondence: Mustafa Mahmut Baris, **E-mail:** mustafamb1@yahoo.com

Received: 24.12.2019; **Accepted:** 26.04.2020; **Available Online Date:** 15.05.2020

©Copyright 2020 by Dokuz Eylul University, Institute of Health Sciences - Available online at www.jbachs.org

Cite this article as: Baris MM, Serinan E, Calisir M, Simsek K, Aktas S, Yilmaz O, Kilic Ozdemir S, Secil M. Xenograft Tumor Volume Measurement in Nude Mice: Estimation of 3D Ultrasound Volume Measurements Based on Manual Caliper Measurements. J Basic Clin Health Sci 2020; 4:90-95.

ABSTRACT

Objectives: Volume measurement of subcutaneous xenograft tumors in nude mice models is an important metric to assess tumor growth or response to therapy. Manual calipers are widely used for this purpose. But the measurements with manual calipers may be inaccurate. Contrarily, three-dimensional (3D) ultrasonographic measurements give reliable and accurate tumor volume calculation. We aim to; evaluate the accuracy of common four formulas given in the literature to estimate xenograft tumor volumes based on manual caliper measurements and offer a new coefficient for a better estimation of the tumor volumes.

Patients and Methods: Detailed manual diameter measurements of xenograft tumors were in 14 nude mice performed using Vernier caliper. Tumor volumes were calculated using the suggested formulas in the literature based on manual measurements. 3D ultrasound volume measurements were performed on same xenograft tumors using high resolution Vevo 2100 imaging system. To propose a new coefficient; means of ratio between manual and ultrasound volume measurement values were used. Also, data set was divided into two subgroups as tumor volume under 800 mm³ and over 800 mm³. New coefficients for each subgroup were defined.

Results: Only with prolate ellipsoid formula there was no statistically significant difference between volume measurements with two methods (p=0,24). Our proposed formula (0,45 L*W*H) could estimate tumor volumes as good as prolate ellipsoid formula. Coefficient 0,35 and 0,81 in the same formula were found efficient in the selected subgroups.

Conclusion: Using one common coefficient/formula for tumor volume estimation in any tumor size can be inaccurate. Appropriate coefficient should be chosen according to the dataset worked with.

Keywords: Tumor volume, nude mice, ultrasonography, 3-D imaging, laboratory animal science

INTRODUCTION

Volume measurement of subcutaneous xenograft tumors in nude mice models is an important metric to assess tumor growth, disease progression or response to therapy (1). Manual calipers (Vernier calipers) are widely used for this purpose due to their noninvasive, rapid and inexpensive nature (1-3). But the measurements with manual calipers may be inaccurate and inconsistent due to several limitations of this method. For example, effect of epidermis and adipose tissue around the tumor mass cannot be excluded with this method properly (1, 4). Additionally, tumors with irregular borders and non-ellipsoid shapes are more problematic to measure with manual caliper method (1, 4). In the manual measurement process with Vernier caliper, usually the longest two dimensions of the tumor can be measured and the third dimension assumed to be the same as

the shortest dimension due to difficulties in height measurement (1, 4). In the literature, Length * Width² / 2 formula (modified Hansen formula) widely accepted for xenograft tumor volume estimations, if calipers are involved (1-7).

There are numerous alternative methods to measure the volume of xenograft tumors as computed tomography (CT) imaging, magnetic resonance imaging (MRI) and bioluminescence imaging (1, 4, 5). Yet, ultrasound imaging has emerged with the advantages of being inexpensive, noninvasive and reliable method for measuring tumor volume in longitudinal studies (1, 7, 8). Also, it has been showed that three-dimensional (3D) ultrasonographic measurements gives reliable and accurate tumor volume calculation (1, 7, 9). But unfortunately, not every laboratory does have high resolution

ultrasonography devices dedicated to small animal imaging. Moreover, using an ultrasound device for measuring tumor volume requires much more expertise than manual calipers.

This led us to think, if there is a better way to predict the actual tumor volume based on manual measurements. In the literature, there are similar concerns for prostate volume measurement and testicular volume measurements (10-12). Hsieh et al. and Paltiel et al. suggested Lambert equation (Formula 4) for the estimation of true testicular volume (6, 10, 12). Similarly, prolate ellipsoid formula (Formula 3) can be used to estimate prostate volume (6, 11). Even there are some studies for estimation of the actual target organ volume by using manual measurements in three axes, to the best of our knowledge, estimation of subcutaneous xenograft tumor volume measured by 3D high resolution ultrasound based on manual caliper measurements has not been studied yet.

There are four commonly used formulas in the literature used to estimate xenograft tumor volume based on caliper measurements:

Ellipsoid volume; (7)

$$V = \frac{4}{3} \pi \cdot x \cdot y \cdot z \quad \text{Formula 1}$$

Volume estimation for caliper measurements-modified Hansen formula; (1, 2, 4-7)

$$V = L \cdot \frac{W^2}{2} \quad \text{Formula 2}$$

Prostate volume-prolate ellipsoid formula; (6, 11)

$$V = 0.52 \cdot L \cdot W \cdot H \quad \text{Formula 3}$$

Estimation of testicular volume - Lambert Formula; (6, 10, 12).

$$V = 0.71 \cdot L \cdot W \cdot H \quad \text{Formula 4}$$

where V: tumor volume, L: length, W: width, H: height, x= L/2, y=W/2, z= H/2

In this study, we aimed to evaluate the accuracy of the four commonly used formulas based on caliper measurements to estimate xenograft tumor volumes measured by 3D high resolution ultrasound. We also aimed to propose a formula with a new coefficient for a better estimation of tumor volume, based on the manual caliper measurements of xenograft tumor.

MATERIALS AND METHODS

Animal model

All animal procedures were approved by the local animal care and use ethical committee. Six-weeks old female atymic nude mice were used as animal model. 4T1 mammary carcinoma cell line was used for tumor growth in nude mice. The 4T1 mammary carcinoma is a syngenic mouse model of breast cancer (13). 4T1 cells (ATCC) were cultured in Rosewell Park Memorial Institute (RPMI)-1640 (Gibco™) containing 10% FBS, 1% penicillin/streptomycin, and 1% L-glutamine. The cells were incubated at 37 °C and 5% CO₂ conditions. All reagents were freshly prepared with mediums before all experiments. The 4T1 cancer cells (4x10⁵) were injected subcutaneously into the posterior superior part of either right or left rear leg of each mouse (13, 14). Injections were performed to 14 nude mice.

Caliper Measurements of subcutaneous Xenograft Tumors

After induction, mice were monitored daily for xenograft tumor growth. In 8 to 10 days after induction, xenograft tumors reached to the measurable size (approximately 9-10 mm in length). Firstly, measurements of length, area and height were performed manually using Vernier caliper by an investigator experienced with collecting caliper measurements of xenograft tumors in mice over 2 years (15). Tumor area measurements were performed using the specific attachment of Vernier caliper and placing it all-around the tumor borders adequately (Figure 1). After four days from the first measurement, second manual measurement was performed to all xenograft tumors.

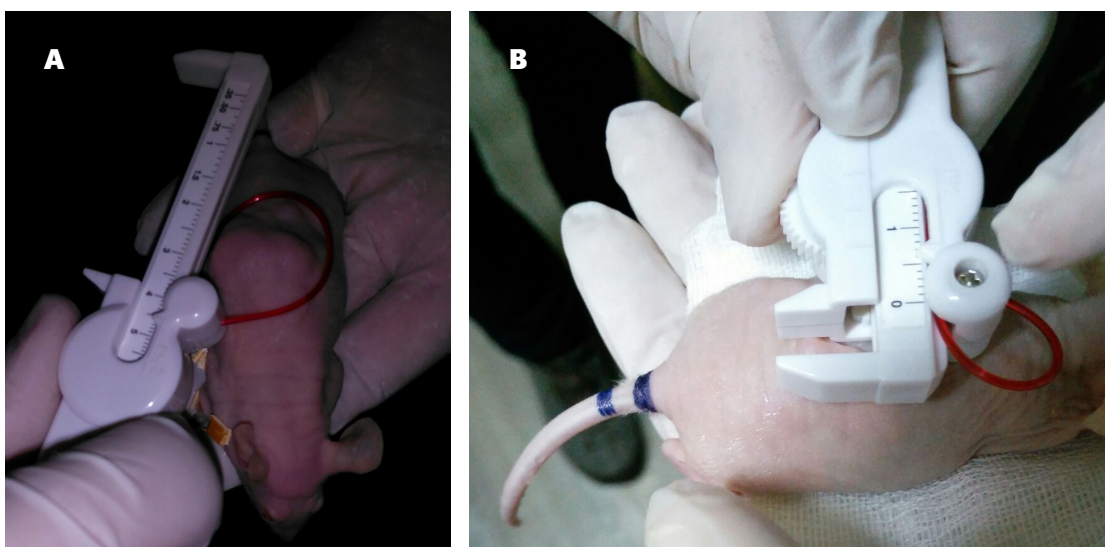


Figure 1 A,B. Manual measurements of the tumor. **A)** area measurement with the specific tool of Vernier caliper, **B)** diameter measurement with Vernier caliper.

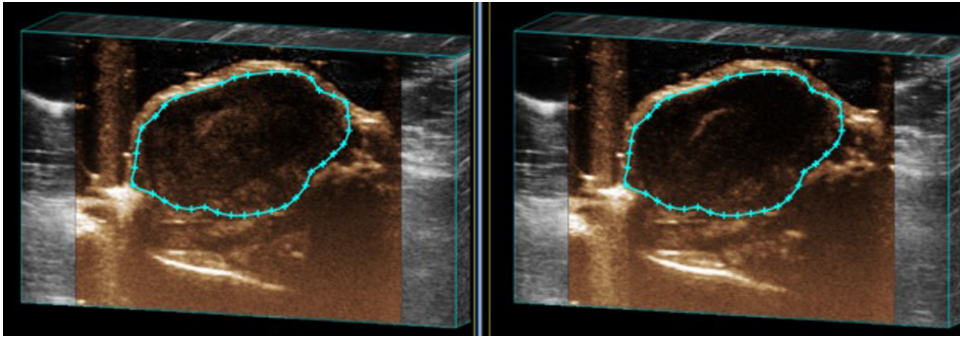


Figure 2. ROI replacements in each slice during 3D Ultrasound volume measurement process.

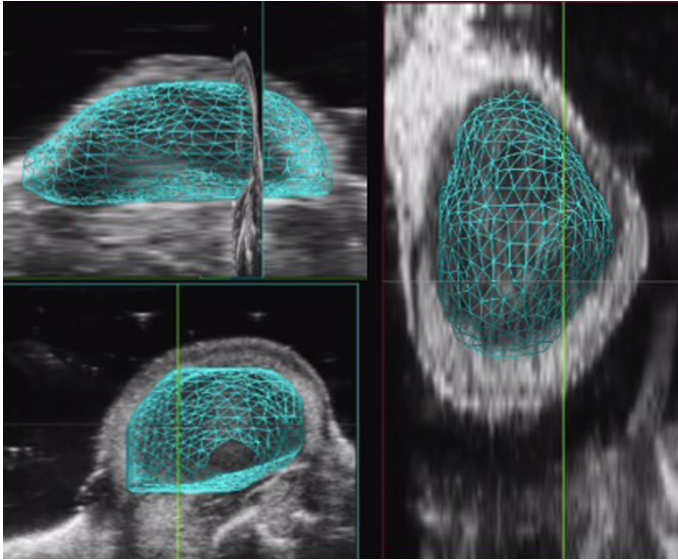


Figure 3. 3D reconstructions of ultrasound imaging data for each xenograft tumor were produced. The segmented xenograft borders are shown in green. Vevo LAB software were used for volume measurement and production of 3D reconstruction images.

Ultrasound measurement method

Simultaneously with the caliper measurements, ultrasound evaluation of tumor and 3D ultrasound volume measurements were performed using high resolution Vevo 2100 imaging system (Fujifilm VisualSonics Inc., Toronto, Canada). 3D ultrasound images were collected for each tumor using Vevo 2100 imaging system high resolution ultrasound device designed for small-animal imaging. Ultrasound evaluation couldn't be performed to one of the nude mice in the second evaluation after the manual measurement due to exitus of the mice during the anesthesia.

For imaging acquisition, the mice were initially anesthetized using %2 isoflurane in oxygen. Mice were placed on a heated evaluation plate during the course of imaging and anesthesia was maintained during imaging using 2% isoflurane in oxygen. Xenograft tumors were coated in warmed (37°C) Aquasonic 100 ultrasound gel (Parker Laboratories, Inc, Fairfield, NJ). Three-dimensional B-mode data were acquired by automated translation of the 55-MHz ultrasound transducer along the entire length of the xenograft with the use of 3D imaging motor attached to the Vevo imaging station. Data set was acquired with 1 mm slice thickness. These continuous images in acquired data set were uploaded to the 3D

imaging software (Vevo LAB- VisualSonics Inc., Toronto, Canada) integrated in Vevo 2100 ultrasound device. With the help of the software, region of interests (ROI) were drawn around the tumor borders on every slice by a radiologist experienced more than ten years in radiology and more than 5 years in laboratory animal imaging (Figure 2). Using this method, the volume measurements for whole xenograft tumor were performed and the software generated the final volume (Figure 3).

Tumor volume estimation

After manual measurements in three axes using Vernier caliper, tumor volumes were calculated using the four formulas given above (1, 2, 4, 10-12, 15).

In Formula 1, the area measurement with Vernier caliper was used to increase the consistency. In fact, Formula 1 and Formula 3 are equivalent, but we used different parameters to create a difference.

In this study, we propose a new formula to estimate xenograft tumor volume (Formula 5), by taking the means of ratio between manual (derived by multiplying manual measurements in three axes) and ultrasound volume measurements.

$$V = 0.45 \cdot L \cdot W \cdot H \quad \text{Formula 5}$$

For further analysis, data set was divided into two subgroups as tumor volume (according to ultrasound measurement) more than 800 mm³ and tumor volume under 800 mm³. The same method (taking the means of ratio between manual and ultrasound measurements) was employed to produce a coefficient for each subgroup.

The calculated tumor volumes derived from each formula were compared with the high-resolution 3D ultrasound volumes statistically.

Statistical analysis

Data were analyzed using SPSS 24 (SPSS Inc., Chicago, IL, USA) program. Shapiro Wilks test was used to determine the appropriateness of the variables to the normal distribution. Non-parametric Wilcoxon signed rank test was used to determine if there is a significant difference between the manual measurements (which is a paired group of data not suitable for normal distribution) and ultrasound measurements. The relationship between the manual measurements and the ultrasound measurements was

evaluated using regression analysis. P value <0.05 was considered statistically significant.

As stated above, ultrasound evaluation couldn't be performed to one of the mice in the second evaluation was not be able to performed due to exitus of the mice during the anesthesia. Manual measurements related to this nude mouse were not used in the statistical analysis. Statistical analysis was performed on 27 manual measurements and related 27 ultrasound measurements.

R-square (R²) is a statistical criterion representing the rate of variance for an independent variable or a dependent variable explained by the variables in a regression model. If the coefficient of explanation (R²) is found close to one, most of the change in the dependent variable can be explained by the independent variable.

RESULTS

Totally, 27 manual and ultrasound measurements were performed. Ultrasound measurements of the tumor mass varied between 67 and 3383 mm³ with a mean volume of 549 mm³. Volume estimations based on the four formulas used in the literature and our proposed formula as well as ultrasound measurements were summarized in Table 1.

As can be seen partially in Table 1, except big tumors, tumor volumes were overestimated in 92% of the cases with manual

measurement methods. In three tumors (ultrasound volumes were higher than 1000 mm³), tumor volumes were underestimated in 67% and comparable in 33% of the cases with manual measurement methods.

Except Formula 3, all other formulas used to predict tumor volume resulted in statistically significantly different results than US measurements (Table 2). Only with Formula 3 there was no statistically significant difference between results (p=0.24). Additionally, mean tumor volume estimated by using Formula 3 was very close to the one estimated by ultrasound measurements.

By our approach, (taking the means of ratio between manual and ultrasound measurements), the coefficients were found to be 0.35 (Formula 6) for small tumor subgroup (tumor volume under 800 mm³) and 0.81 (Formula 7) for large tumor subgroup (tumor volume over 800 mm³), respectively (Table 3).

$$\text{Tumor volume} < 800 \text{ mm}^3 \quad V = 0.35 \cdot L \cdot W \cdot H \quad \text{Formula 6}$$

$$\text{Tumor volume} > 800 \text{ mm}^3 \quad V = 0.81 \cdot L \cdot W \cdot H \quad \text{Formula 7}$$

The tumor volumes determined using the Formula 3, Formula 5 and Formula 6 for small tumor volume group were compared. A statistically significant difference was found between the assumed volumes obtained by the coefficient 0.52 (Formula 3) (p=0.001), coefficient 0.45 (Formula 5) (p=0.006) and the ultrasound volume measurements. But there was no statistically significant difference

Table 1. Volume estimations with the four-common formula, our proposed formula and volume measurement with ultrasound (US).

Method	Min. volume	Max. volume	Mean volume (± std.deviation)
Formula 1	200	2200	700 ±431
Formula 2	162	2688	693 ±512
Formula 3	140	1747	535 ±339
Formula 4	192	2386	730 ±464
Formula 5	121	1512	463 ±294
US volume measurement	67	3383	549 ±726

Table 2. Comparison between each datasets & estimation models

	Volume Difference Formula & Ultrasound (mm ³) (mean ± sd; median (min-max))	P value	Estimation Model	Volume Difference Prediction & Ultrasound (mm ³) (mean±sd; median (min-max))	P value	R ²
Formula1 & Ultrasound	151.5 ± 389.4; 151.5 ((-1183)-720)	0.01**	Linear	0 ± 321; 12.45(-628.3-717.8)	0.92**	0.805
Formula2 & Ultrasound	144.7 ± 333.2; 199 ((-749)-670.5)	0.01**	Linear	0 ± 297; -2.75(-674.1-744.3)	0.95**	0.833
Formula3 & Ultrasound	-14 ± 447; 115 ((-1636)-544)	0.24**	Linear	0 ± 319; -0.42(-601.3-742)	0.87**	0.807
Formula4 & Ultrasound	181.5 ± 370.8; 237 ((-997.4)-772)	0.005**	Linear	0 ± 319; -0.42(-601.3-742)	0.87**	0.807
Formula5 & Ultrasound	86.1 ± 480.2 ; -51.9 ((-460)-1871)	0.737**	Linear	0 ± 319; 0.40(-742-601)	0.866**	0.807

**Based on results of nonparametric Wilcoxon signed rank test.

Table 3. Subgroup analyze and suggested coefficients for each group.

Volume group	n	Mean±sd of group ratio
All	27	0.45±0.31
< 800 mm ³	21	0.35±0.26
> 800 mm ³	6	0.81±0.18

Volume Group	Coefficient	Difference for Formula & Ultrasound (mm ³) (mean±sd; median (min-max))	p value
< 800 mm ³	0.52	156.2 ± 171.3; 138.8 (-294.8 - 544)	0.001**
	0.45	99.8 ± 159.3; 87.2 (-320 - 460)	0.006**
	0.35	19.5 ± 148.6; 22.5 (-356 - 340)	0.543**
> 800 mm ³	0.52	609.7 ± 611.8; 349.4 (62 - 1635.8)	0.028**
	0.45	736.9 ± 666.2; 432.8 (173.8 - 1871)	0.028**
	0.81	82.5 ± 399.16; 3.88 (-400 - 661.4)	0.600**

**Based on results of nonparametric Wilcoxon signed rank test.

between the volumes calculated using Formula 6 and the ultrasound volume measurements (p>0.005).

The tumor volumes determined by using Formula 3, Formula 5 and Formula 7 were compared for the large tumor volume group (tumor volume over 800 mm³). Same as above, there was no statistically significant difference between the volumes obtained by the Formula 7 (p>0.005) and the ultrasound measurements, while tumor volumes determined by Formula 3 and Formula 5 were found to be significantly different (p=0.028, p=0.0028) (Table 3).

DISCUSSION

To verify the consistency of the four commonly used formulas in the calculation of tumor volume, we compared the calculated tumor volumes with the ones measured with 3D high resolution ultrasound which is a reliable and accurate method for tumor volume estimation (1, 9). Only Formula 3 ($V = 0.52 \cdot L \cdot W \cdot H$ - prolate ellipsoid formula) results indicated no statistically significant difference from the ultrasound measurement results. Other three formulas were statistically significantly different from ultrasound volume measurements. Although Formula 2 is a widely used formula in the literature and being referred in more than 48 papers (1, 2, 4, 6), our study showed that tumor volume estimation with prolate ellipsoid formula (Formula 3) gives more accurate results than Formula 2.

Also, to be used in manual measurements, we tried to develop a formula with a new coefficient which enables tumor volume measurements as accurate as the ultrasound measurements. We found that our suggested formula (formula 5 with the coefficient of 0.45) can estimate the tumor volumes measured by ultrasound as good as Formula 3. Both formulas have %65 fit ratio with ultrasound measured volumes and have statistically no significant difference. Yet, our proposed formula does not have any advantageous to the well-known and widely used Formula 3.

It has been shown that interobserver variability and error in volume measurements with manual calipers increase when small

tumor masses were measured (3). This error decreases in the case of large tumor masses. We used 800 mm³ tumor volume as cut point to define small tumor mass group and larger tumor mass group. There were two reasons for choosing 800 mm³ as cut point. First of all, we experienced that manual measurement of tumor volume was more accurate and easier if the tumor was larger than 9-10 mm in length ($\cong 700-1000$ mm³). Secondly, in our data, there was only three mice with tumor mass over 1000 mm³ and when we chose 800 mm³ as a cut of point, we found that the groups were more comparable. Our subgroup analysis showed that suggested subgroup coefficients (0.35 for small tumor subgroup and 0.81 for large tumor subgroup) can estimate tumor volume more accurately than a single coefficient for whole group. That is, we suggest that if the data set consists of small tumors with the volume under 800 mm³, Formula 6 can be used to estimate tumor volumes in manual caliper measurements.

In our study group, manual measurement methods underestimated the volumes of three tumors, whose sizes were higher than 1000 mm³ according to ultrasound measurements. Except these three big tumor masses, manual measurement method resulted in overestimated tumor volumes. We attributed the overestimated results to the effect of epidermis and adipose tissue around the tumor (1, 4), while underestimated results can be related to height of the tumor. In our study, we observed that the tumors with higher than 1000 mm³ volume were reaching the deep soft tissue, while tumors under 1000 mm³ stayed more superficial. In one specific sample, we observed that high volume tumor passed through vertebral transvers processes and reached to the prevertebral level. From these, we conclude that manual caliper measurement has limited capacity to estimate the real height of a tumor if the tumor has components in deep tissue plans.

Our main limitation is lack of pathological correlation of actual tumor volume using water displacement method. However, many studies showed that high resolution ultrasound volume measurements are very accurate and reliable (1, 7, 9). Therefore, we planned to estimate ultrasound volumes of the tumors without pathological correlation.

In conclusion, Formula 3 generally can estimate 3D ultrasound volume of xenograft tumors in nude mice better than other three formulas used in the literature. But, using a single formula for volume estimation in all tumor sizes may results in inaccurate volume measurements. Appropriate formula/coefficient should be chosen according to the dataset worked with. If the dataset consists of small xenograft tumors with the volume under 800 mm³, Formula 6 can be used for accurate xenograft tumor volume estimation. If the data consists of larger xenograft tumors (>800 mm³), Formula 7 gives more accurate results.

Informed Consent: It is an animal study.

Compliance with Ethical Standards: The research was carried out with the approval of the Dokuz Eylül University Animal Experiments local Ethics Committee (No: 04/13, Date: 09.06. 2015).

Peer-review: Externally peer-reviewed.

Author Contributions: Concept - MB, MS; Design - MB, SA; Supervision - MB, MS SO, KS; Fundings - OY, SO, SA; Materials - OY, SA, ES, MC; Data Collection and/or Processing - MB, KS, ES, MC; Analysis and/or Interpretation - MB, KS, OY; Literature Search - MB, ES, MC; Writing Manuscript - MB, SO; Critical Review - MB, MS

Conflict of Interest: No conflict of interest was declared by the authors.

Financial Disclosure: This study was financially supported by The Scientific and Technological Research Council of Turkey (TUBITAK) under grant number 213M668.

REFERENCES

- Ayers GD, McKinley ET, Zhao P, et al. Volume of Preclinical Xenograft Tumors Is More Accurately Assessed by Ultrasound Imaging Than Manual Caliper Measurements. *J Ultrasound Med* 2010;29:891-901. [\[CrossRef\]](#)
- Tomayko MM, Reynolds CP. Determination of Subcutaneous Tumor Size in Athymic (Nude) Mice. *Cancer Chemother Pharmacol* 1989;24:148-154. [\[CrossRef\]](#)
- Euhus DM, Hudd C, LaRegina MC, Johnson FE. Tumor Measurement in the Nude-Mouse. *J Surg Oncol* 1986;31:229-234. [\[CrossRef\]](#)
- Kersemans V, Cornelissen B, Allen PD, Beech JS, Smart SC. Subcutaneous tumor volume measurement in the awake, manually restrained mouse using MRI. *J Magn Reson Imaging* 2013;37:1499-1504. [\[CrossRef\]](#)
- Jensen MM, Jørgensen JT, Binderup T, Kjaer A. Tumor volume in subcutaneous mouse xenografts measured by microCT is more accurate and reproducible than determined by 18F-FDG-microPET or external caliper. *BMC Med Imaging* 2008;8:16. [\[CrossRef\]](#)
- Lin CC, Huang WJS, Chen KK. Measurement of Testicular Volume in Smaller Testes: How Accurate Is the Conventional Orchidometer? *J Androl* 2009;30:685-689. [\[CrossRef\]](#)
- Cheung AM, Brown AS, Hastie LA, et al. Three-dimensional ultrasound biomicroscopy for xenograft growth analysis. *Ultrasound Med Biol* 2005;31:865-870. [\[CrossRef\]](#)
- Graham KC, Wirtzfeld LA, MacKenzie LT, et al. Three-dimensional high-frequency ultrasound imaging for longitudinal evaluation of liver metastases in preclinical models. *Cancer Res* 2005;65:5231-5237. [\[CrossRef\]](#)
- Pflanzer R, Hofmann M, Shelke A, et al. Advanced 3D-Sonographic Imaging as a Precise Technique to Evaluate Tumor Volume. *Translational Oncology* 2014;7:681-686. [\[CrossRef\]](#)
- Paltiel HJ, Diamond DA, Di Canzio J, Zurakowski D, Borer JG, Atala A. Testicular volume: Comparison of orchidometer and US measurements in dogs. *Radiology* 2002;222:114-119. [\[CrossRef\]](#)
- Matthews GJ, Motta J, Fracchia JA. The accuracy of transrectal ultrasound prostate volume estimation: Clinical correlations. *J Clin Ultrasound* 1996;24:501-505. [\[CrossRef\]](#)
- Hsieh ML, Huang ST, Huang HC, Chen Y, Hsu YC. The reliability of ultrasonographic measurements for testicular volume assessment: comparison of three common formulas with true testicular volume. *Asian J Androl* 2009;11:261-265. [\[CrossRef\]](#)
- Przybyla BD, Shafirstein G, Vishal SJ, Dennis RA, Griffin RJ. Molecular changes in bone marrow, tumor and serum after conductive ablation of murine 4T1 breast carcinoma. *Int J Oncol* 2014;44:600-608. [\[CrossRef\]](#)
- van Gelder M, Vanclée A, van Elssen CHM, Hupperets P, Wieten L, Bos GM, Bone marrow produces sufficient alloreactive natural killer (NK) cells in vivo to cure mice from subcutaneously and intravascularly injected 4T1 breast cancer. *Breast Cancer Res Treat* 2017;161:421-433. [\[CrossRef\]](#)
- Carlsson G, Gullberg B, Hafström L. Estimation of Liver-Tumor Volume Using Different Formulas - an Experimental-Study in Rats. *J Cancer Res Clin Oncol* 1983;105:20-23. [\[CrossRef\]](#)